

# Microneedling Therapy With and Without Platelet-Rich Plasma

Peter W. Hashim, MD, MHS; Zachary Levy; Joel L. Cohen, MD; Gary Goldenberg, MD

## PRACTICE POINTS

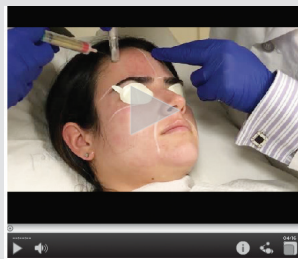- Microneedling is an effective therapy for skin rejuvenation.
- Preliminary evidence indicates that the addition of platelet-rich plasma to microneedling improves cosmetic outcomes.

*Microneedling therapy is an increasingly popular treatment of several dermatologic conditions. Platelet-rich plasma (PRP) may serve as a valuable adjunct to improve the regenerative effects of treatment. We review the evidence comparing the results of microneedling therapy with and without PRP. Based on the current preliminary literature, PRP appears to augment the cosmetic outcomes of microneedling without increasing the risk for adverse events.*

*Cutis.* 2017;99:239-242.

### VIDEO ONLINE

Microneedling With Platelet-Rich Plasma  
 >> Demonstrated by  
 Gary Goldenberg, MD  
 >> <http://bit.ly/2o1aOOS>



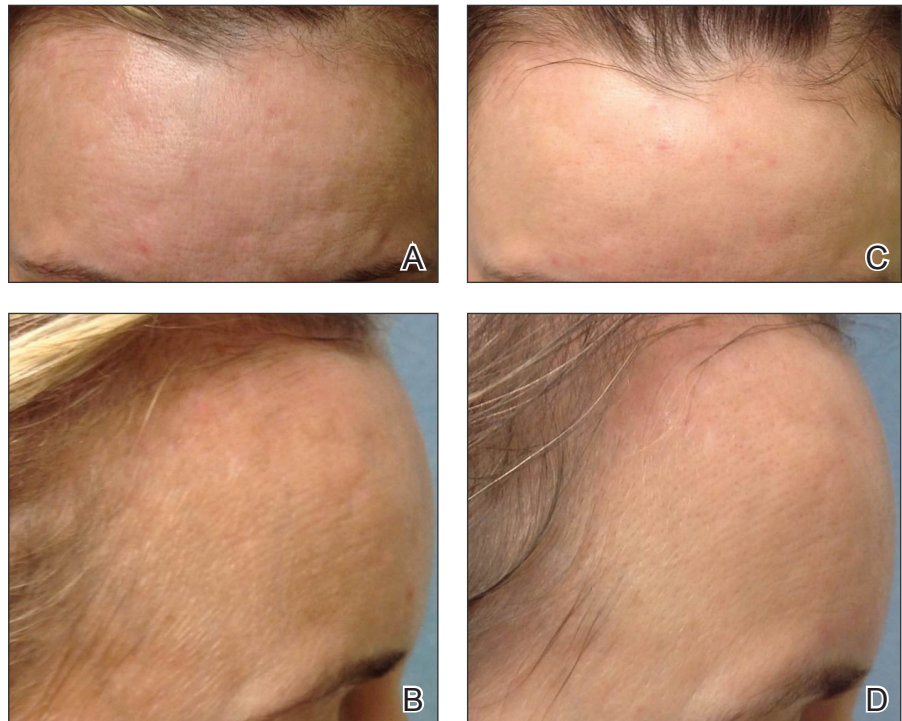
Drs. Hashim and Goldenberg and Mr. Levy are from the Department of Dermatology, Icahn School of Medicine at Mount Sinai, New York, New York. Dr. Cohen is from AboutSkin Dermatology and DermSurgery, Greenwood Village, Colorado; the Department of Dermatology, University of Colorado Denver, Aurora; and the Department of Dermatology, University of California, Irvine. Drs. Hashim and Goldenberg and Mr. Levy report no conflict of interest. Dr. Cohen is an advisory board member, clinical researcher, and consultant for Allergan, Inc, and Galderma Laboratories, LP; a consultant and speaker for Sciton, Inc; and a clinical researcher for CROMA-PHARMA GmbH and Suneva Medical, Inc. Correspondence: Gary Goldenberg, MD, Department of Dermatology, Icahn School of Medicine at Mount Sinai, 5 E 98th St, New York, NY 10029 (garygoldenbergm@gmail.com).

Microneedling therapy, also known as collagen induction therapy or percutaneous collagen induction, is an increasingly popular treatment modality for skin rejuvenation. The approach employs small needles to puncture the skin and stimulate local collagen production in a minimally invasive manner. Recently, clinicians have incorporated the use of platelet-rich plasma (PRP) with the aim of augmenting cosmetic outcomes. In this article, we examine the utility of this approach by reviewing comparison studies of microneedling therapy with and without the application of PRP.

## Microneedling Therapy

The use of microneedling first gained attention in the 1990s. Initially, Camirand and Doucet<sup>1</sup> described tattooing without pigment for the treatment of achromatic and hypertrophic scars. Fernandes<sup>2</sup> evolved this concept and developed a drum-shaped device with fine protruding needles to puncture the skin. Microneedling devices have expanded in recent years and now include both cord- and battery-powered pens and rollers, with needles ranging in length from 0.25 to 3.0 mm.

Treatment with microneedling promotes skin rejuvenation by creating small puncture wounds in the epidermis and dermis. This injury triggers the wound healing cascade and alters the modulation of growth factors to promote regenerative effects.<sup>3,4</sup> Following microneedling therapy, increases occur in elastic fiber formation, collagen deposition, and dermal thickness (Figure).<sup>5</sup> Of interesting histologic note, collagen is deposited in the normal lattice pattern following this treatment rather than in the parallel bundles typical of scars.<sup>6</sup> Microneedling preserves the overall integrity of the epidermal layers



Before (A and B) and after skin rejuvenation with 4 sessions of microneedling therapy (C and D). Photographs courtesy of Joel L. Cohen, MD (Colorado, USA).

and basement membrane, allowing the epidermis to heal without abnormality, verified on histology by a normal stratum corneum, enhanced stratum granulosum, and normal rete ridges.<sup>7</sup>

Microneedling has demonstrated several uses beyond general skin rejuvenation. In patients with atrophic acne scars, therapy can lead to improved scar appearance, skin texture, and patient satisfaction.<sup>8,9</sup> Hypertrophic and dyspigmented burn scars on the body, face, arms, and legs have shown to be receptive to repeated treatments.<sup>10</sup> Microneedling also has shown promise in treating androgenic alopecia, increasing hair regrowth in patients who previously showed poor response to conventional therapy with minoxidil and finasteride.<sup>11,12</sup>

### Platelet-Rich Plasma

Platelet-rich plasma is developed by enriching blood with an autologous concentration of platelets. The preparation of PRP begins with whole blood, commonly obtained peripherally by venipuncture. Samples undergo centrifugation to allow separation of the blood into 3 layers: platelet-poor plasma, PRP, and erythrocytes.<sup>13</sup> The typical platelet count of whole blood is approximately 200,000/ $\mu\text{L}$ ; PRP aims to prepare a platelet count of at least 1,000,000/ $\mu\text{L}$  in a 5-mL volume.<sup>14</sup>

An attractive component of PRP is its high concentration of growth factors, including platelet-derived growth factor, transforming growth factor, vascular endothelial growth factor, and epithelial growth factor.<sup>15</sup> Because of the regenerative effects of these

proteins, PRP has been investigated as a modality to augment wound healing in a variety of clinical areas, such as maxillofacial surgery, orthopedics, cardiovascular surgery, and treatment of soft tissue ulcers.<sup>16</sup>

### Combination Use of Microneedling and PRP

Several studies have compared the effects of microneedling with and without the application of PRP (Table).<sup>17-20</sup> In an animal model, Akcal et al<sup>17</sup> examined the effects of microneedling and PRP on skin flap survival. Eight rats were randomly divided into 5 groups: sham, control, microneedling alone, microneedling plus PRP, and microneedling plus platelet-poor plasma. Treatments were applied to skin flaps after 4 hours of induced ischemia. The surviving flap area was measured, with results demonstrating significantly higher viable areas in the microneedling plus PRP group relative to all other groups ( $P < .01$ ). On histologic examination, the microneedling plus PRP group showed well-organized epidermal layers and a dermal integrity that matched the dermis of the sham group.<sup>17</sup>

Asif et al<sup>18</sup> performed a split-face comparison study of 50 patients with atrophic acne scars. On the right side, microneedling was performed followed by intradermal injections and topical application of PRP. On the left side, microneedling was performed followed by intradermal injections of distilled water. The study included 3 treatment sessions with 1 month between each session. Scars were assessed using the Goodman and Baron scale,<sup>21</sup> which is designed to

## Microneedling and PRP in Patients With Acne Scars

Reference (Year)	Study Design	N	Mean Age of Patients (Range), y	Treatment Groups	Treatment Protocol	Results	Adverse Effects
Asif et al <sup>18</sup> (2016)	Nonrandomized, unblinded	50	25.7 (17–32)	Right side of face: microneedling + PRP; left side of face: microneedling + distilled water	6 passes in 4 directions with a 1.5-mm needle; 3 treatments at 1-mo intervals	Microneedling + PRP: 62% improvement in scarring; microneedling + distilled water: 46% improvement in scarring	No long-term adverse effects
Fabbrocini et al <sup>19</sup> (2011)	Nonrandomized, unblinded	12	32.2 (18–45)	Right side of face: microneedling + PRP; left side of face: microneedling alone	10–14 passes in 4 directions with a 1.5-mm needle; 2 treatments at 8-wk intervals	Microneedling + PRP: 47% improvement in scarring; microneedling alone: 35% improvement in scarring	No long-term adverse effects
Chawla <sup>20</sup> (2014)	Nonrandomized, unblinded	30	27.5 (18–34)	Right side of face: microneedling + PRP; left side of face: microneedling + vitamin C	8–10 passes in 4 directions with a 1.5-mm needle; 4 treatments at 1-mo intervals	Microneedling + PRP: good or excellent response in 78% of patients; microneedling + vitamin C: good or excellent response in 63% of patients	One patient experienced severe PIH

Abbreviations: PRP, platelet-rich plasma; PIH, postinflammatory hyperpigmentation.

grade the morphology of postacne scarring. Scars on the right side improved by 62.2% and scars on the left side improved by 45.8%; prior to treatment, both sides demonstrated similar severity scores, but final severity scores were significantly reduced in the microneedling plus PRP group relative to the microneedling plus distilled water group ( $P < .00001$ ). No residual side effects from treatment were reported.<sup>18</sup>

Examining the degree of improvement more carefully, microneedling plus PRP yielded excellent improvement in 40% (20/50) of patients and good improvement in 60% (30/50).<sup>18</sup> Microneedling plus distilled water led to excellent improvement in 10% (5/50) and good improvement in 84% (42/50). Given that microneedling plus distilled water still provided good to excellent results in 94% of patients, the addition of PRP was helpful though not necessary in achieving meaningful benefit.<sup>18</sup>

In another split-face study, Fabbrocini et al<sup>19</sup> evaluated 12 adult patients with acne scars. The right side of the face received microneedling

plus PRP, while the left side received microneedling alone. Two treatments were performed 8 weeks apart. Severity scores (0=no lesions; 10=maximum severity) were used to assess patient outcomes throughout the study. Acne scars improved on both sides of the face following the treatment period, but the reduction in scar severity with microneedling plus PRP (3.5 points) was significantly greater than with microneedling alone (2.6 points) ( $P < .05$ ). Patients tended to experience 2 to 3 days of mild swelling and erythema after treatment regardless of PRP addition. With only 12 patients, the study was limited by a small sample size. The 10-point grading system differed from the Goodman and Baron scale in that it lacked corresponding qualitative markers, likely decreasing reproducibility.<sup>19</sup>

Chawla<sup>20</sup> compared the effectiveness of combination therapy with microneedling plus PRP versus microneedling and vitamin C application. In a split-face study of 30 patients with atrophic acne scars, the right side of the face was treated with microneedling

plus PRP and the left side was treated with microneedling plus vitamin C. Four sessions were performed with an interval of 1 month in between treatments. The Goodman and Baron Scale was used to assess treatment efficacy. Overall, both treatments led to improved outcomes, but in categorizing patients who demonstrated poor responses, a significantly larger percentage existed in the microneedling plus vitamin C group (37% [10/27]) versus the microneedling plus PRP group (22% [6/27]) ( $P=.021$ ). Additionally, aggregate patient satisfaction scores were higher with microneedling plus PRP relative to microneedling plus vitamin C ( $P=.01$ ). Of note, assessments of improvement were performed by the treating physician and patient satisfaction reports were completed with knowledge of the therapies and cost factor, which may have influenced results.<sup>20</sup>

## Conclusion

Microneedling therapy continues to evolve with a range of applications now emerging in dermatology. As PRP has gained popularity, there has been increased interest in its utilization to amplify the regenerative effects of microneedling. Although the number of direct comparisons examining microneedling with and without PRP is limited, the available evidence indicates that the addition of PRP may improve cosmetic outcomes. These results have been demonstrated primarily in the management of acne scars, but favorable effects may extend to other indications. Continued study is warranted to further quantify the degree of these benefits and to elucidate optimal treatment schedules.

In addition, it is important to consider a cost-benefit analysis of PRP. The price of PRP varies depending on the clinical site but in certain cases may double the cost of a microneedling treatment session. Although studies have demonstrated a statistically significant benefit to PRP, the clinical significance of this supplementary treatment must be weighed against the increased expense. A discussion should take place with the consideration that microneedling alone can provide a satisfactory result for some patients.

## REFERENCES

1. Camirand A, Doucet J. Needle dermabrasion. *Aesthetic Plast Surg*. 1997;21:48-51.
2. Fernandes D. Percutaneous collagen induction: an alternative to laser resurfacing. *Aesthet Surg J*. 2002;22:307-309.
3. Fabbrocini G, Fardella N, Monfrecola A, et al. Acne scarring treatment using skin needling. *Clin Exp Dermatol*. 2009;34:874-879.
4. Zeitter S, Sikora Z, Jahn S, et al. Microneedling: matching the results of medical needling and repetitive treatments to maximize potential for skin regeneration [published online February 7, 2014]. *Burns*. 2014;40:966-973.
5. Schwarz M, Laaff H. A prospective controlled assessment of microneedling with the Dermaroller device. *Plast Reconstr Surg*. 2011;127:E146-E148.
6. Fernandes D, Signorini M. Combating photoaging with percutaneous collagen induction. *Clin Dermatol*. 2008;26:192-199.
7. Aust MC, Fernandes D, Kolokythas P, et al. Percutaneous collagen induction therapy: an alternative treatment for scars, wrinkles, and skin laxity. *Plast Reconstr Surg*. 2008;121:1421-1429.
8. El-Domyati M, Barakat M, Awad S, et al. Microneedling therapy for atrophic acne scars: an objective evaluation. *J Clin Aesthet Dermatol*. 2015;8:36-42.
9. Leheta T, El Tawdy A, Abdel Hay R, et al. Percutaneous collagen induction versus full-concentration trichloroacetic acid in the treatment of atrophic acne scars. *Dermatol Surg*. 2011;37:207-216.
10. Aust MC, Knobloch K, Reimers K, et al. Percutaneous collagen induction therapy: an alternative treatment for burn scars. *Burns*. 2010;36:836-843.
11. Dhurat R, Mathapati S. Response to microneedling treatment in men with androgenetic alopecia who failed to respond to conventional therapy. *Indian J Dermatol*. 2015;60:260-263.
12. Dhurat R, Sukesh M, Avhad G, et al. A randomized evaluator blinded study of effect of microneedling in androgenetic alopecia: a pilot study. *Int J Trichology*. 2013;5:6-11.
13. Wang HL, Avila G. Platelet rich plasma: myth or reality? *Eur J Dent*. 2007;1:192-194.
14. Marx RE. Platelet-rich plasma (PRP): what is PRP and what is not PRP? *Implant Dent*. 2001;10:225-228.
15. Lubkowska A, Dolegowska B, Banfi G. Growth factor content in PRP and their applicability in medicine. *J Biol Regul Homeost Agents*. 2012;26(2 suppl 1):3S-22S.
16. Pietrzak WS, Eppley BL. Platelet rich plasma: biology and new technology. *J Craniofac Surg*. 2005;16:1043-1054.
17. Akcal A, Savas SA, Gorgulu T, et al. The effect of platelet rich plasma combined with microneedling on full venous outflow compromise in a rat skin flap model. *Plast Reconstr Surg*. 2015;136(4 suppl):71-72.
18. Asif M, Kanodia S, Singh K. Combined autologous platelet-rich plasma with microneedling verses microneedling with distilled water in the treatment of atrophic acne scars: a concurrent split-face study [published online January 8, 2016]. *J Cosmet Dermatol*. 2016;15:434-443.
19. Fabbrocini G, De Vita V, Pastore F, et al. Combined use of skin needling and platelet-rich plasma in acne scarring treatment. *Cosmet Dermatol*. 2011;24:177-183.
20. Chawla S. Split face comparative study of microneedling with PRP versus microneedling with vitamin C in treating atrophic post acne scars. *J Cutan Aesthet Surg*. 2014;7:209-212.
21. Goodman GJ, Baron JA. Postacne scarring: a qualitative global scarring grading system. *Dermatol Surg*. 2006;32:1458-1466.